Current techniques for echocardiographic imaging of the mitral regurgitation

Sebastian Sawonik[1], Marek Prasał[2], Radosław Gęca[2], Jacek Zawiślak[2], Andrzej Wysokiński[2], Maciej Wójcik[2]

[1] Department of Cardiology, Mazovia Regional Hospital in Siedlce, Poland

[2] Department of Cardiology, Medical University of Lublin, Poland

European Journal of Medical Technologies
2019; 1(22): 34-44

www. medical-technologies.eu
Published online 15.02.2019

Abstract

We present current methods of mitral regurgitation imaging (MR). A number of echocardiographic methods of mitral valve regurgitation imaging obligates to know their capabilities and limitations. This review is based on a list of current publications outlining methods of echocardiographic mitral valve regurgitation imaging.

Echocardiography is one of the most important ways to diagnose MR. Color Doppler flow mapping is the basic technique to diagnose MR. There are five different modalities of this technique: regurgitant jet area, vena contracta, proximal isovelocity surface area (PISA), continuous wave Doppler and pulsed Doppler. These methods of echocardiographic imaging could be performed during transthoracic echocardiography (TTE) and transesophageal echocardiography (TEE). Transesophageal echocardiography should be considered when TTE cannot provide optimal quality, or when thrombosis, endocarditis or prosthetic valve dysfunction are suspected. Furthermore, the role of exercise testing is important. Standard exercise stress test is useful to prove the presence of symptoms in daily activities. Two-dimensional (2D) echocardiography is a very useful and usually sufficient tool in daily clinical practice. On the other hand, 2D-echocardiography is less precise in left ventricle size assessment and determining the precise location of valve lesions in comparison to simultaneous multiplane 3D-echocardiography.

Each imaging modality has both advantages and limitations. The choice of imaging modality should be individualized on a case-by-case basis so that each technique is used to its best possible application.

Corresponding address:
Sebastian Sawonik
Department of Cardiology, Mazovia Regional Hospital in Siedlce
Księcia Józefa Poniatowskiego 26,
08-110 Siedlce, Poland
e-mail: s.sawonik@wp.pl

Key words:

mitral valve regurgitation, echocardiography

Introduction

Mitral valve regurgitation (MR) is the second most frequent, after aortic valve stenosis, valve disease in Europe.[1] Echocardiography is an important tool to diagnose MR, which continues to be an important cause of morbidity and mortality. Regular imaging can reveal progression of mitral valve (MV) regurgitation, the effects of surgical treatment or pharmacotherapy. The treatment depends on the etiology of this illness. There multiple etiologies of primary MV regurgitation (degeneration, inflammation, infection, congenital defect, tissue, iatrogenic, disruption or trauma) as well as a number of secondary regurgitation (functional regurgitation) where myocardium remodeling affects the structurally normal valve. In clinical regurgitation there are three types of MR: type I – extension, or degeneration of the mitral annulus; type II – increased leaflet motion, caused by prolapse, or cordal elongation, cordal rupture, papillary muscle elongation, papillary muscle rupture; type III – diminished or restricted leaflet motion (type IIIa – diastolic restriction, e.g. post rheumatic damage caused by leaflet thickening or retraction, cordal thickening or shortening, commissural fusion and type IIIb – systolic restriction, e.g. ischemic etiology where papillary muscle displacement or leaflet tethering could be observed). [1,2,3]

Objectives

We present various methods of mitral regurgitation imaging. Echocardiography plays a very important role in MR diagnosis and is crucial in qualifying MR for various ways of treatment. A large number of echocardiographic methods of imaging obligates a physician to know the advantages and disadvantages of each one, which is the key to proper interpretation of patient's condition.

Material and methods

The following research is based on a list of current publications outlining basic and new methods of echocardiographic mitral valve regurgitation imaging. Analysis, synthesis, followed by general conclusions served as a basis for the interpretation of these data. Furthermore, the graphic examples are based on the authors' own clinical practice.

A study of various methods of mitral valve imaging in echocardiography

Transthoracic echocardiography (TTE) and transesophageal echocardiography (TEE) are two main methods in mitral valve imaging. Transesophageal echocardiography should be considered when TTE cannot provide optimal quality, or when thrombosis, endocarditis or prosthetic valve dysfunction are suspected. Furthermore, TEE is used during percutaneous mitral interventions and is helpful in evaluating the results of surgical valve treatment and percutaneous valve implantation.

A diagnosis of MR using TTE valve morphology depends on the etiology of MR (flail leaflet, ruptured papillary muscle, or large coaptation). As far as qualitative methods are concerned, Color Doppler echocardiography imaging includes the estimation of: central jet, eccentric jet, adhering jet, swirling jet as well as the jet reaching the posterior wall of left atrium. Furthermore, large flow convergence zone can be observed at a Nyquist limit of 50–60 cm/s. Additional semiquantitative method is the evaluation of *vena contracta* width – upstream vein flow presents systolic pulmonary vein flow reversal. Early mitral diastolic filling i.e. E-wave dominant ≥1,5 m/s in the absence of other causes of elevated left atrial (LA) pressure or mitral stenosis, points to MR. Effective regurgitant orifice area (EROA) is another quantitative method: EROA ≥40 mm^2 indicates severe primary MR, while EROA ≥20 mm^2 indicates severe secondary MR. In order to identify a group of patients with increased risk of cardiac events, it is important to define the etiology as different thresholds are used in secondary MR (regurgitant volume s >30 mL and EROA >20 mm^2). [3,4,5,6]

To ensure proper diagnosis of MR, the size of left ventricle (LV), left ventricular ejection fraction

(LVEF), the volume of left atrium, the pressure of systolic pulmonary artery, the size of both tricuspid regurgitation, tricuspid annulus and the right ventricle function should be evaluated. [7]

Current techniques for echocardiographic imaging of mitral regurgitation

Color Flow Doppler

Color Doppler flow mapping is the primary technique to screen MR. There are five different modalities implementing Doppler effect.

Regurgitant jet area

As the evaluation of regurgitant jet area is very reliable for excluding MR, it provides inaccurate data for grading MR severity. Patients who have low arterial blood pressure and elevated pressure in left atrium might show small color flow jet area despite (acute) severe MR. On the other hand, patients with hypertension and mild MR could have a large jet area. Moreover, jet area depends on the mechanism governing MR (e.g. eccentric jet in patients with flail leaflet). The measurements of MR can be also overestimated and underestimated (small jet area could be a sign of spreading jet along the cardiac wall). [7,8,9]

Vena contracta (width and area)

Vena contracta (Fig. 1) is the measurement of the effective regurgitant orifice. In normal circumstances it should be imaged in a parasternal long-axis view to receive *vena contracta* width. *Vena contracta* (VC) ≥0,7 cm is specific for severe MR, while VC<0,3cm indicates mild MR. This imaging method is adequate for both central and eccentric jets. Accurate definition of *vena contracta* may be corrupted by jet's shape (noncircular, or multiple jets raise a chance to underestimate the parameter). Three dimentional (3D) echocardiography also allows for VC assessment (by manual planimerty of the colour Doppler signal). Multiple jest should be measured one by one. Only the highest velocity should be measured (aliasity). Unfortunately, the evaluation of *vena contracta* has

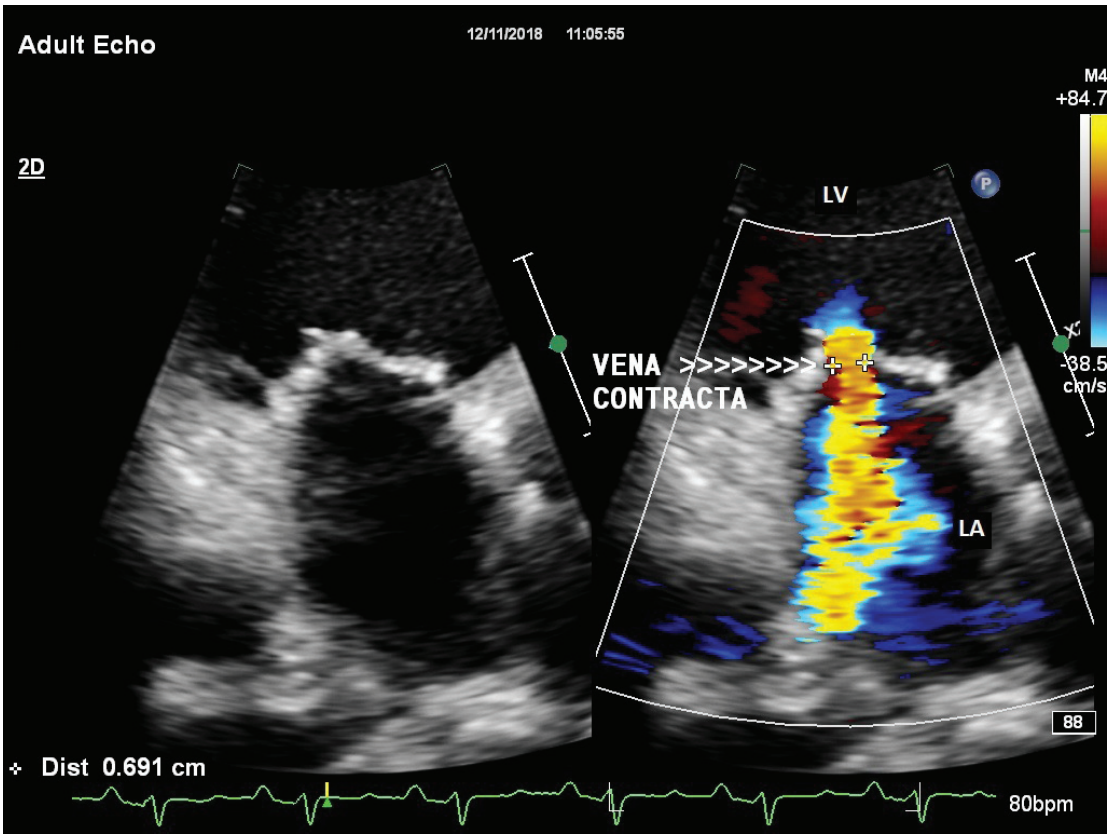

Fig. 1.
Vena contracta. Two dimensional echocardiography. LA – left atrium, LV – left ventricle

few crucial limitations: dynamic variation in the regurgitant orifice and blooming effect (the signal is larger than jet core itself). Moreover the shape of regurgitant jet is important in secondary MR. [10]

Flow convergence (PISA)

The PISA (proximal isovelocity surface area) method is used to estimate the area of an orifice. PISA is considered the most accurate method to assess the MR severity. [11] The condition is that the mitral regurgitant orifice is circular. That is why this method is proper for central and circular jets rather than for eccentric and noncircular ones. In Color Doppler imaging the hemispheres can become more flattened, or more cone-shaped. Furthermore, the hemisphere is always considered as complete hemisphere (if one of the mitral leaflets restricts the flow, or ventricular wall restricts the hemisphere – "angle correction factor" should be applied). In case of multiple regurgitant orifices, the flow convergence method may be completely inaccurate in estimating the EROA. Although identifying the aliasing line is usually easy, the accurate location of the orifice could be very difficult to establish. Statistically we can talk about 10–25% of errors in measurement (the smallest one for central jets). That is why using various imaging methods should be considered in every patient with MR. Due to the fact that regurgitant orifice is often crescent-shaped in secondary MR, circular shape of orifice should not be assumed (because of the risk of underestimation). A simplified approach to PISA quantitation has been also validated. This simplification does not hold at the extremes of blood pressure but the vast majority of patients have jets between 4 and 6 m/sec for which this approximation is reasonable. [12]

Continuous Wave Doppler (CWD)

In most patients, maximum MR velocity is 4-6 m/sec due to the high systolic pressure gradient between the LV and LA. That is why peak systolic MR velocity does not provide useful information about the volumetric severity of MR, but it does provide clues to the hemodynamic consequences of MR. A low MR peak velocity (e.g. 4 m/sec) suggests hemodynamic compromise (low blood pressure/elevated LA pressure). In addition to peak velocity, the contour of the velocity profile and its density are useful. A truncated, triangular jet contour with early peaking of the maximal velocity indicates elevated LA pressure or a prominent regurgitant pressure wave. The density of the Continuous Wave Doppler (CWD) signal is a qualitative index of MR severity; a dense signal suggests significant MR, whereas a faint signal is likely to be mild or trace MR. Continuous Wave Doppler should also be used to interrogate the tricuspid regurgitation (TR) jet to estimate pulmonary artery (PA) systolic pressure, another indirect clue for MR severity.

Pulsed Doppler

Pulsed Doppler methods can be used to measure stroke volumes at the level of LV outflow tract. Relative volume can also be calculated by comparing two variables: Doppler left ventricular outflow tract stroke volumes and total left ventricular stroke volumes. As two dimensional (2D) echocardiography tends to underestimate left ventricle (LV) volume, 3D method should be used (ultrasound contrast should be applied in some cases to identify endocardial borders). Pulsed Doppler is commonly used to evaluate LV diastolic function. [11] Patients with severe MR have a dominant early filling. The mitral inflow pattern is also more reliable for assessing primary MR as compared to secondary MR. In secondary MR it is difficult to determine whether 'E wave' dominance is due to significant MR or elevated LV filling pressures. The peak 'E wave' velocity is also affected by smallest degree of mitral stenosis in the presence of rheumatic disease, mitral annular calcification, or a mitral annular ring. [7,11]

Pulmonary Vein Flow (PVF)

Pulmonary Vein Flow measurement is a useful additional method for evaluating the hemodynamic consequences of MR. With increasing severity of MR, there is a depletion of the systolic velocity, culminating with systolic flow reversal in severe MR. PVF measurement is limited in case of left atrium pressure elevation as it could result in blunted systolic forward flow. If the MR is confined to late systole, flow reversal could be additionally used with other parameters. However, the

finding of systolic flow reversal (in more than one pulmonary vein) is specific for severe MR. It is also important to distinguish true systolic flow reversal from contamination by the MR jet itself, which is a more difficult task during TTE (evaluation of PVF is easier in TEE). [7,11]

Assessment of LV and LA Volumes

Primary significant MR triggers a pure volume overload of the LV. If chronic, such a condition would result in LV dilation and untreated can lead to its ultimate dysfunction. It is important to consider a body size in evaluating the LV size. On the other hand, in secondary MR, the relation between LV dilation and MR severity is not clear because MR results are not always the effect of LV dysfunction but also may contribute to it. Additionally, it is important to measure both LV chamber size and its function in order to determine the need for surgical or percutaneous intervention and to measure any reverse LV remodeling after therapy. Three-dimensional echocardiography is now recommended for evaluation of LV volumes as it offers improved precision compared to 2D echocardiography. Echocardiographic measurements of global longitudinal strain may become useful in evaluating earlier myocardial dysfunction in MR that could be masked by volume-based measurements, such as LV ejection fraction (LVEF).

Left atrial dilation is also the expected consequence of severe MR. A normal LA size generally excludes severe chronic MR. LA volumes are superior to LA diameters in evaluating LA dilation and in predicting atrial fibrillation. However, LA dilatation can occur in other medical conditions, including hypertension and atrial fibrillation. Therefore, a dilated LA does not necessarily imply severe MR. [10]

Role of Exercise Testing

Due to the fact, that severe compensated MR can be asymptomatic for years, standard exercise stress test is useful to prove the presence of symptoms in daily activities. Echocardiographic stress tests could be performed in three different ways: dobutamine stress echocardiography (DSE) or exercise echocardiography using either a treadmill or a bicycle ergometer. Paradoxically, the severity of MR can decrease during dobutamine provocation if left ventricle systolic function decreases at the same time. Pharmacologic stress echocardiography plays no role in determining the severity of mitral regurgitation, except when ischaemia could be distinguished (patients, who cannot take a part in physical exercise test, as ischaemia may be the cause of MR). Low-dose DSE could be useful also in ischaemic heart disease to determine viable myocardium, which may influence management of ischaemic MR. Moreover, echocardiographic scanning during treadmill exercise test is not feasible and has to be performed after exercise ideally within 60-90 seconds. Ergometer testing gives the chance to obtain images during various levels of physical effort. Nevertheless, obtaining echocardiographic images during exercises is a very demanding task and it is not always possible to perform. [10]

Role of TEE in Assessing Mechanism and Severity of MR

Transesophageal echocardiography (Fig. 2, 3, 4, 5) is performed usually when transthoracic echocardiography results does not give clear conclusions. TEE is preferred to identify the mechanism of mitral regurgitation (it is the best method for valve pathology evaluation and before planning surgical or percutaneous treatment). Furthermore, VC imaging and PISA method are easier to perform and can be more precise during TEE. Moreover, TEE offers better imaging of pulmonary veins flow than TTE. If TEE is performed under sedation, patient`s blood pressure should be monitored (lower blood pressure could influence MR assessment). Due to the fact that quantitative pulsed is very demanding (pulsed wave Doppler is limited by wave angulation which can lead to inaccurate measure of systemic output), it is the most affected quantitative MR parameter with TEE. [3,5,7,13]

2D technique

In the daily practice, the use of two-dimensional echocardiography (Fig. 6, 7, 8, 9) and Doppler procedures are mostly sufficient and it is first-choice technique for evaluation of MR. This method is operator-dependent and can be affected by limited cut-planes. Simultaneous multiplane 3D-echocardiography

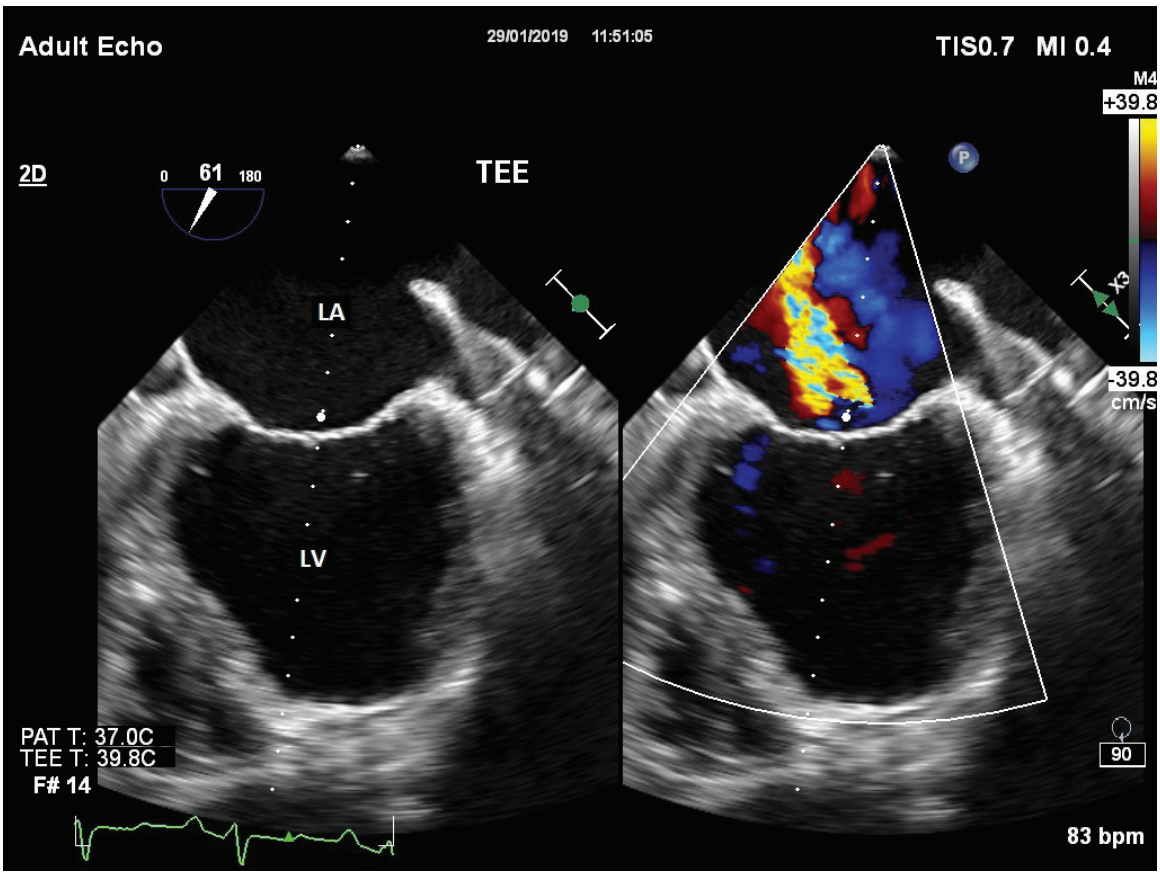

Fig. 2.
Two dimensional transesophageal echocardiography

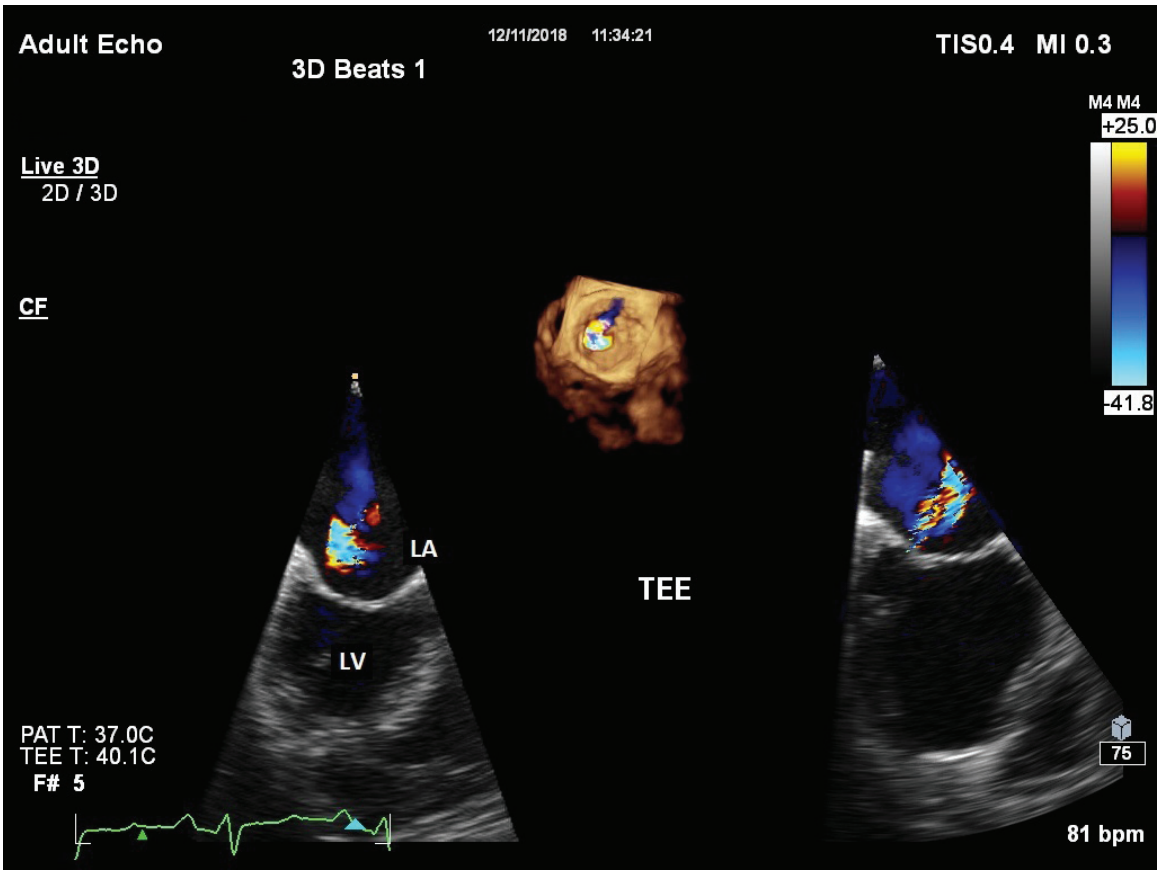

Fig. 3.
Comparison of three dimensional transesophageal echocardiography and two dimensional transesophageal echocardiography

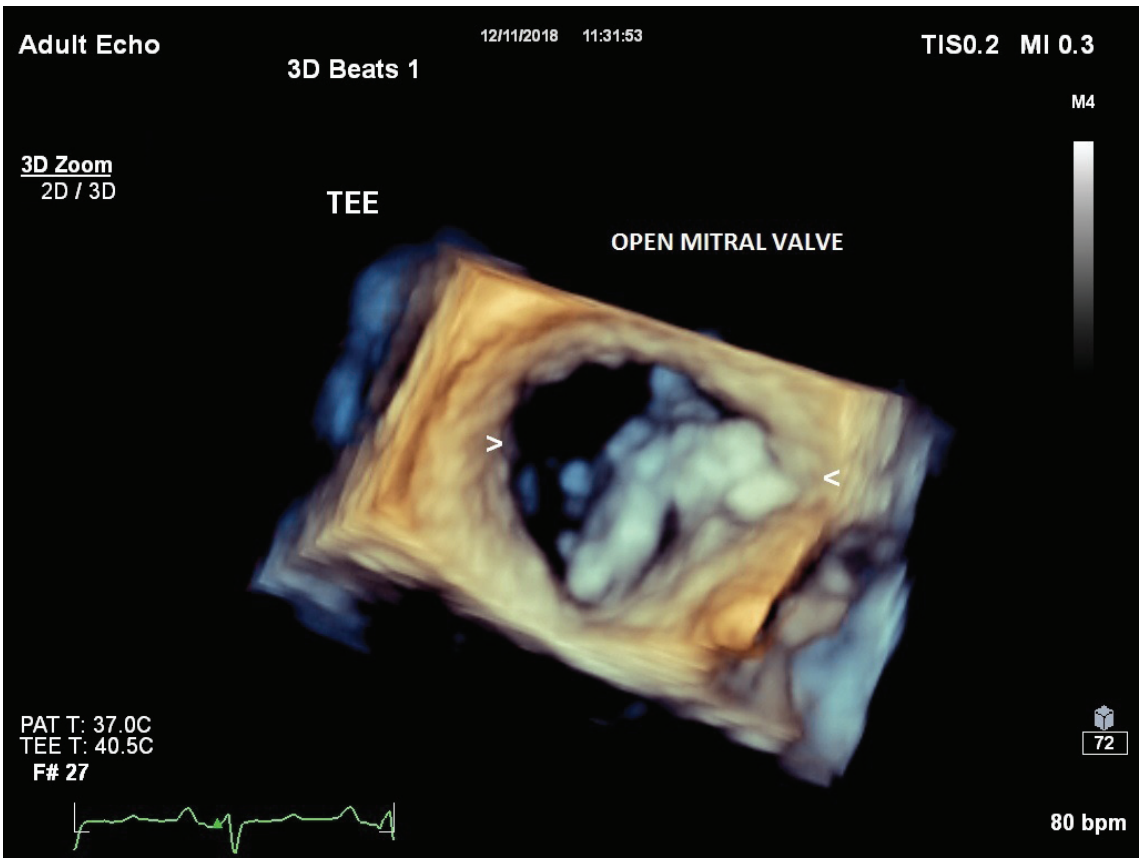

Fig. 4.
Three dimensional transesophageal echocardiography. Open mitral valve.

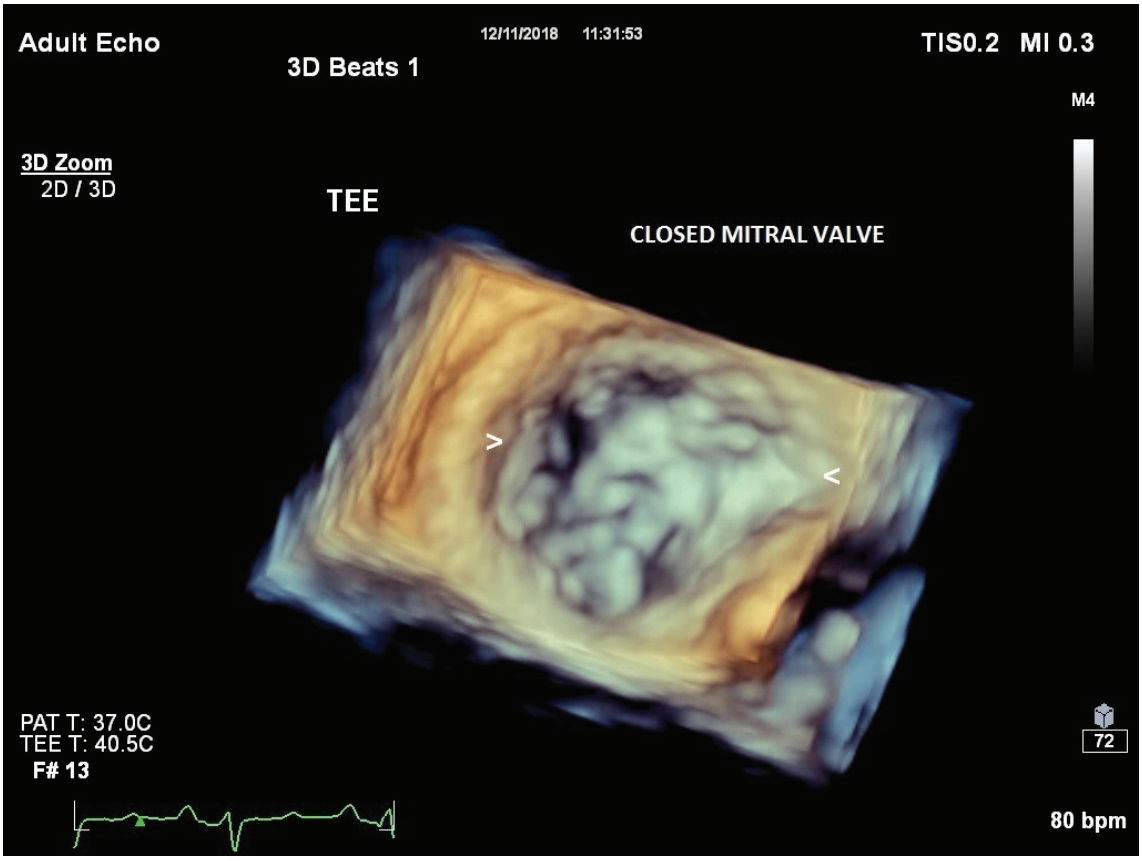

Fig. 5.
Three dimensional transesophageal echocardiography. Closed mitral valve

determines the precise location of valve lesions. 3D-PISA more precisely determines EROA in mitral valve prolapse more precisely but it shows inaccurate EROA results in functional MR (in comparison with 2D-quantitative Doppler). The inaccuracies can be caused by specific elongated geometry of PISA in functional regurgitation (not hemispheric in shape, which is obligatory for reliable calculations). That is why in patients suffering only from functional regurgitation, EROA calculation has to be based on 2D – quantitative Doppler. However, 3D – EROA planimetry is a better tool for measuring eccentric jet. As long as TTE is based on mathematical calculations (size of ventricles, its geometry), Cardiovascular Magnetic Resonance (CMR) imaging is more precise method for determining MR severity. [7]

3D technique versus real-time three-dimensional reconstruction

Three-dimensional echocardiography (Fig. 10) is a widely used echocardiographic technique nowadays. It allows to obtain data during one heart beat (real time three dimensional echocardiography – RT3D echocardiography). Real-time three-dimensional reconstruction (denoted as four dimensional echocardiography) is a technique which eliminates numerous artifacts (observed in previous 3D full volume technique, where several heart beats were analyzed). Additionally, RT3D technique is more precise in patients with arrythmia. Four dimensional echocardiography overcomes the limitations of previous methods, because it allows to reach a full 3D volumetric data set with simultaneous evaluation of multidirectional wall motion. [13] This approach is widely used in both TTE and TEE. In TTE accurate MV imaging is possible in apical projection. TEE is better to determine the grade of MR and to pinpoint the etiology of MR due to the very precise analysis of MV cusps and mitral annulus. TEE is also a good tool to control the function of grafts implanted in mitral position. Furthermore 3D TEE technique has become the current standard for monitoring the procedure of percutaneous paravalvular leak closure. [7,14,15]

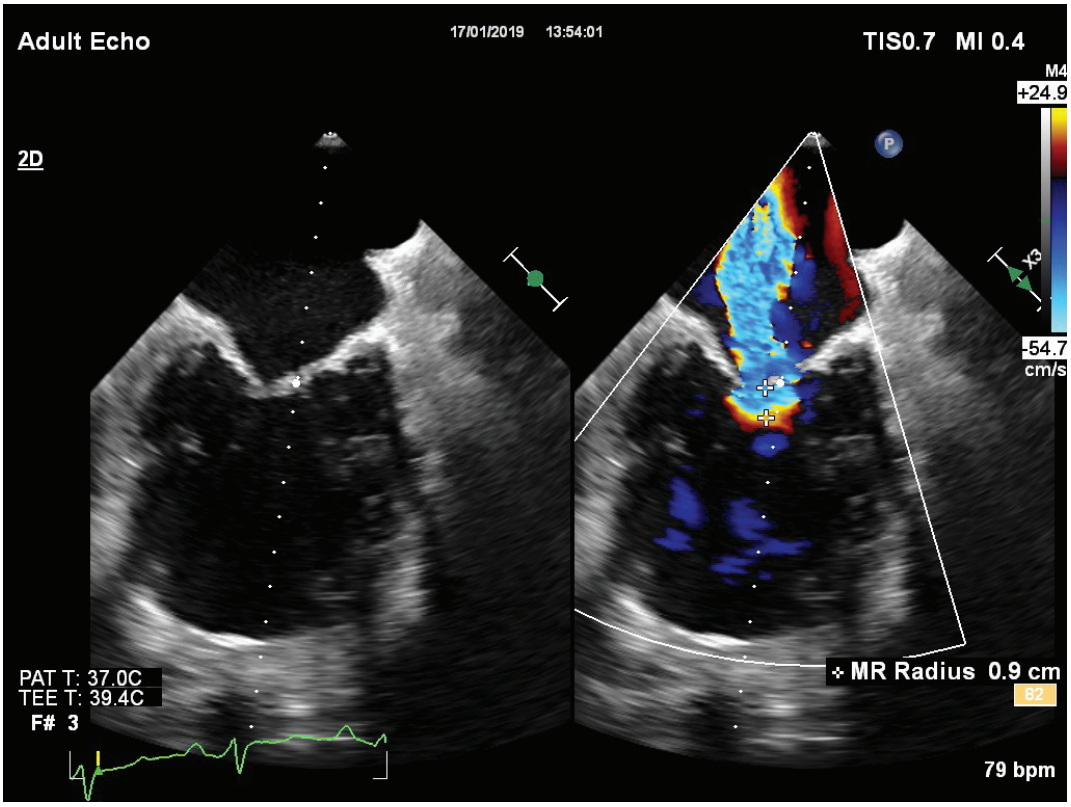

Fig. 6.
Two dimensional echocardiography. Color Doppler flow technique with regurgitant jet

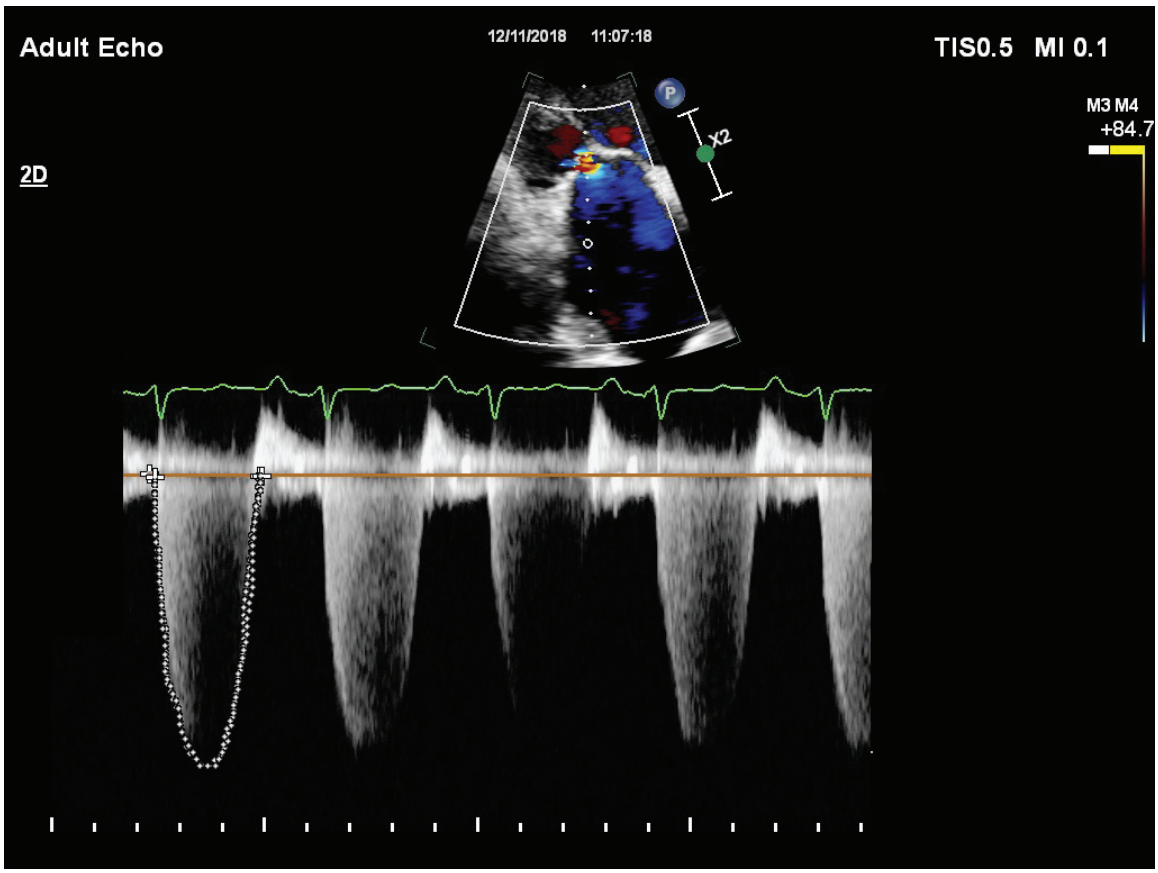

Fig. 7.
Mitral regurgitation jet with maximal flow velocity (Vmax) of 434 cm/s

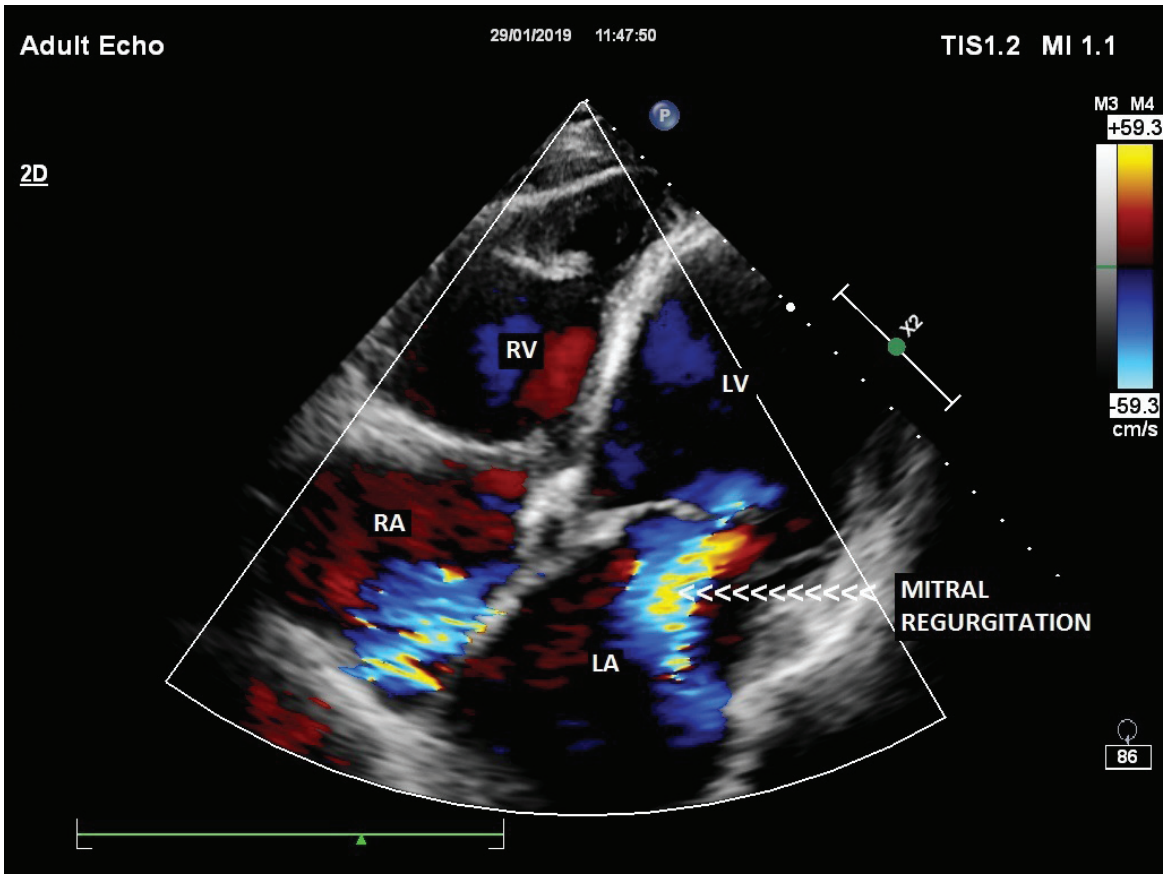

Fig. 8.
Indicated mitral valve regurgitation. LA- left atrium, LV – left ventricle, RA – right atrium, RV – right ventricle

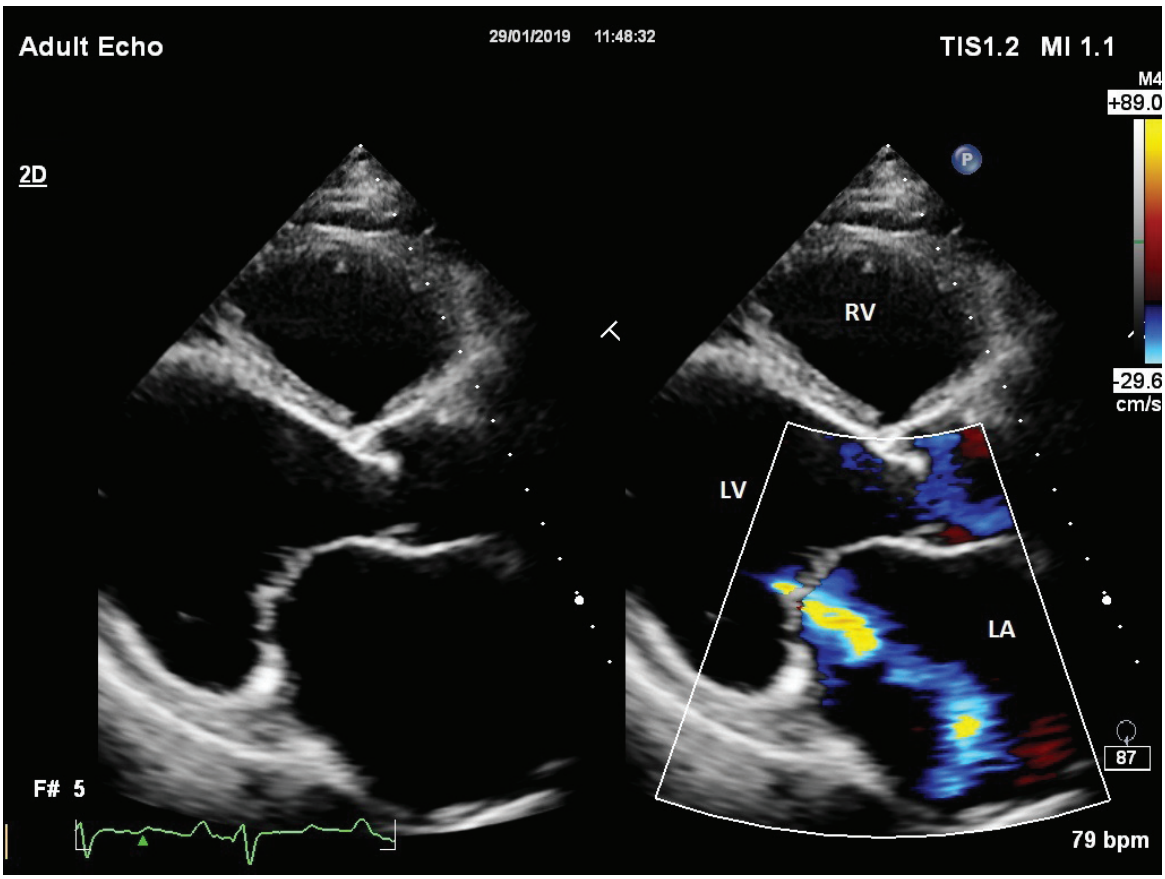

Fig. 9.
Two dimensional echocardiography. Mitral regurgitation visualized in Color Doppler technique

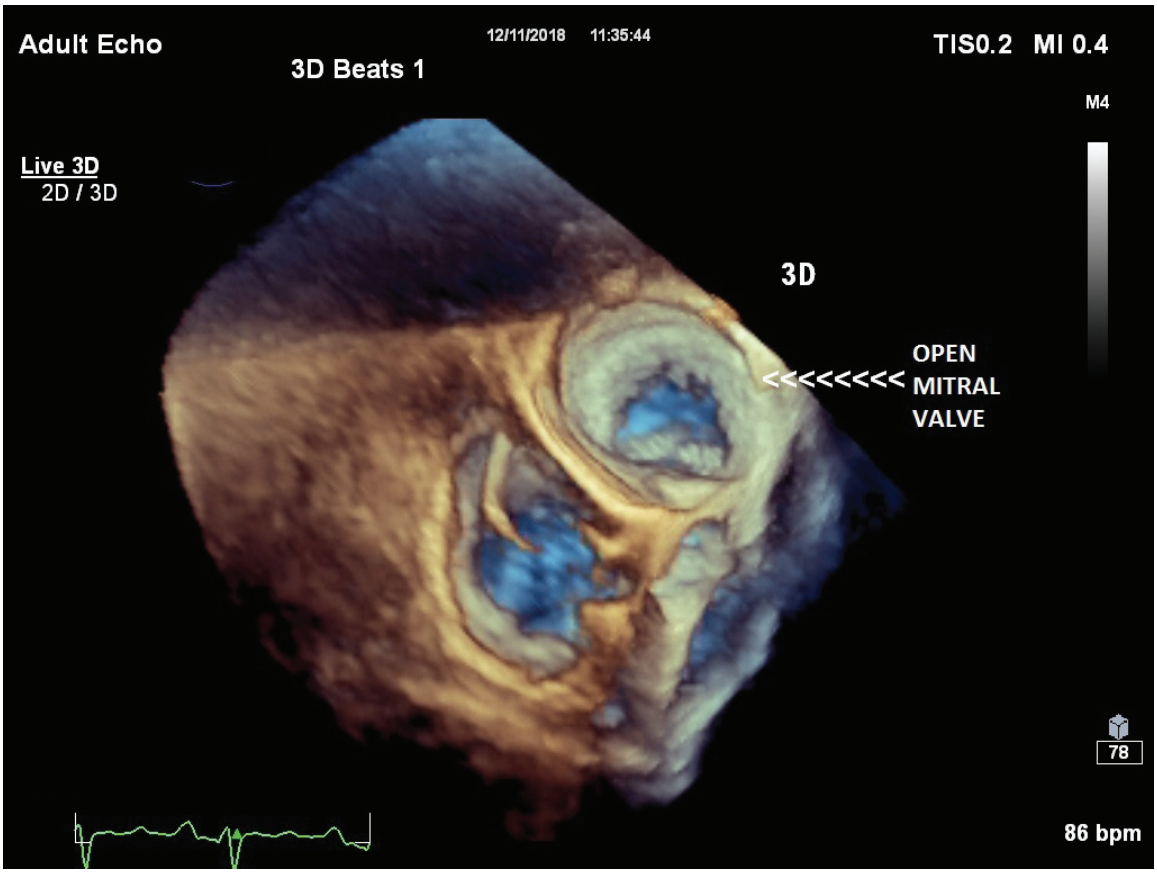

Fig. 10.
Three dimensional transthoracic echocardiography. Open mitral valve

Conclusions

As each imaging modality has both advantages and limitations, an integrated multimodality imaging approach is essential for a comprehensive assessment of MR. Although echocardiography is widely accessible and offers excellent morphological and functional information, it is limited by its suboptimal reproducibility of imaging results with reference to severity assessment and in evaluation of secondary MR. Cardiovascular Magnetic Resonance is highly accurate to establish MR severity and should be considered as a method of choice especially in cases of eccentric MR and in patients with poor echocardiographic window. Cardiac Computed Tomography provides structural information of MV. The choice of imaging modality should be individualized on a case-by-case basis so that each technique is used to its best possible application.

References

1. Chew Pei G., Bounford K., Plein S. et al. Multimodality imaging for the quantitative assessment of mitral regurgitation. Quant Imaging Med Surg. 2018 Apr; 8(3): 342–359.
2. Olszowska M. Elementarz echokardiograficzny wad serca – podsumowanie. Kardiologia po dyplomie. 2009 Jul; 8 (7): 27-30.
3. Zoghbi W. A., David Adams D., Bonow R. O. et al. Recommendations for Noninvasive Evaluation of Native Valvular Regurgitation. ASE Guidelines and standards. 2017 Apr; 30 (4) 305-312.
4. Zalewski J., Nessler J. Niedomykalność zastawki mitralnej. Część II. diagnostyka. Via Medica Journales Kardiol Inwazyjna 2016;11(2):13-16.
5. Capoulade R., Piriou N., Serfaty J., M., et al. Multimodality imaging assessment of mitral valve anatomy in planning for mitral valve repair in secondary mitral regurgitation. J Thorac Dis 2017; 9(7): S640-S660.
6. Sonecki P. Nowe techniki w kardiologii: echokardiografia 3D. Kardiologia po Dyplomie 2010; 9(11): 36-45.
7. Baumgartner H., Falk V., Bax J., J. 2017 ESC/EACTS Guidelines for the management of valvular heart disease. European Heart Journal. 2017; 38, 2739–2786.
8. Anwar A.M. Understanding the role of echocardiography in the assessment of mitral valve disease. E-Journal of Cardiology Practice. 2018 Aug; 16(20).
9. Lancellotti P., Tribouilloy C., Hagendorff A. et al. Scientific Document Committee of the European Association of Cardiovascular Imaging. Recommendations for the echocardiographic assessment of native valvular regurgitation: an executive summary from the European Association of Cardiovascular Imaging. Eur Heart J Cardiovasc Imaging. 2013;14:611-644.
10. Brandt R.R., Nishimura R.A. Understanding the role of echocardiography in mitral valve disease: what is the added value of exercise and drugs on the various echocardiographic parameters? E-Journal of Cardiology Practice. 2018 Oct; 16(25).
11. Tabata T., Thomas J., D., Klein Al., L. Pulmonary Venous Flow by Doppler Echocardiography: Revisited 12 Years Later. JACC 2003; 41 (8): 1243-1250.
12. Alharthi M. S., Tajik J., Mookadam F. Echocardiographic quantitation of mitral regurgitation. Expert Rev. Cardiovasc. Ther. 2008; 6(8): 1151–1160.
13. Hamada S., Altiok E., Frick M. et al. Comparison of accuracy of mitral valve regurgitation volume determined by three-dimensional transesophageal echocardiography versus cardiac magnetic resonance imaging. Am J Cardiol. 2012 Oct;110(7):1015-1020.
14. Hahn, R. Recent advances in echocardiography for valvular heart disease. 2015 Sep; 4: 914.
15. Wunderlich N. C., Beigel R., Siew Y. H. et al. Imaging for Mitral Interventions. JACC: Cardiovascular Imaging. 2018 Oct; 11(6), 872–901.